

Out With the Old and In With the New

by Diane Molinaro, CPCP

What do we do when we have clients walk through our doors with double eyebrow tails, poorly placed pigment, pigment too dark to color correct or give a lighter version, or even pigment the client just wants totally GONE? Well, my usual answer to any of these situations is REMOVAL!

Tattoo removal methods can include laser, surgical removal through incision or cryosurgery, dermabrasion, chemical agents, as well as other products specifically manufactured or formulated for tattoo removal. All tattoo removal methods, with the exception of surgical methods, require a series of treatments to either lighten or remove the unwanted tattoo. All methods seem to carry a varying degree and risk of scarring. Laser is likely the most expensive process, and critics point out that the ink or pigment particles are broken up instead of being removed. This leads to the question of where these particles go after they are broken up, i.e., through the lymphatic system and captured there forever, broken down, or somehow carried out of the body? Salabrasion, or scrubbing the unwanted tattoo with table salt, is listed on the internet as a do-it-yourself method, but will very likely result in scarring and significant pain as the individual uses the table salt to open and then abrade the skin.

Of interest to permanent cosmetics professionals are those methods or products specifically developed for tattoo removal, and often referred to as forms of liquid tattoo removal. Liquid removal methods include commercially formulated products, as well as saline removal procedures performed by properly trained professionals.

The very first step for any technician interested in removal or pigment lightening services is to check with the regulating or licensing agencies in your area. Some regulations mandate that tattoo removal may only be performed by physicians. It is up to you as a technician to find out the regulations that apply to your permanent cosmetic practice, and the services you can and cannot perform according to those regulations.

If you are allowed to perform tattoo removal

according to the regulatory agency in your area, then the next step is to research insurance requirements with your current carrier or with a carrier that covers this service. Before spending money on training, find out about all the requirements of the insurance carrier, including any training or certification, to obtain coverage for you to perform this service. If it is a covered service with your current insurance carrier, will there be an additional fee? If it is not covered, the choice may be to purchase separate coverage from another carrier that will cover you when you perform this service. It may mean completely changing carriers to cover all the services provided by your business in order to have the most cost effective and complete coverage. It often pays to compare rates from different carriers to get the best coverage at the best price. You will likely also need to supply the carrier with copies of all paperwork used for the pigment removal process, such as a health and medical history questionnaire, consent forms, and written client aftercare instructions. Some insurance carriers insure for each type of removal product you use, such as saline, as well as other brands of commercial tattoo removal products now available. Each time you add a particular product to your services, you need to advise your insurance carrier and confirm that you are insured to use that product!

Most important of all, DO NOT, and I repeat DO NOT, attempt removal unless you have been properly trained in the method of removal you intend to use. The basic steps hold true for most all removal or lightening products, but there ARE variables when it comes to needle size and configurations, machine speed, area of the body where the removal can be done, age of the tattoo, as well as how many times correction, removal, or laser have been attempted. These are just a few of the many things you need to know before proceeding.

Non-laser Removal (through use of a liquid removal product):

Before proceeding with any liquid removal procedure,

it is imperative that the client has realistic expectations about the results that can be attained, the number of treatments required, all associated costs, the healing process, risk of scarring or changes in pigmentation, as well as the aftercare steps that must be adhered to for optimal results. Inability to strictly comply with the aftercare protocol may interfere with the success of the product and the procedure results.

Photo documentation of each visit and each step of the process, along with written procedure notes are essential. Not only can these document and validate procedure results, they can also be used for client reference. With any procedure that involves multiple steps, it is often necessary to provide the client with visual evidence and a reminder of what the original tattoo looked like, as well as the improvement attained with each step in the process.

Any liquid removal method involves opening up the tattooed area of the skin where removal is desired by using the recommended needle in the device of your choice (machine or hand tool), and according to the manufacturer or product protocol. Ideally the tattoo pigment resides in the upper dermal level of the skin. Once proper access is achieved, the product can be applied to the open area and left to work for the designated time based on product instructions. Because of the ingredients used in liquid removal products, it is common for the solutions to be acidic or alkaline in nature (rather than neutral), to cause a stinging or burning sensation, and to be somewhat uncomfortable, especially for the first few minutes after application. Some clients, who have also had laser treatments, report that even though the liquid removal process is uncomfortable, it is not as bad as laser removal.

The liquid removal methods may also require fewer sessions than laser removal to obtain desired results; however it is VERY important NOT to create false expectations for the client regarding the number of sessions required to achieve the desired outcome. It is also especially important to fully disclose how the treated area will look during the healing phase. Post procedure or manufacturer pictures of other tattoo removal cases can help prepare the client for the appearance of the hard crust or scabbing that will occur, as well as the importance of allowing it to fall

off naturally.

Once the procedure is completed, follow the recommended aftercare protocol for cleaning and care for the product used. The importance of the client fully understanding the aftercare involved, as well as a commitment for compliance, cannot be overstated. Written aftercare instructions should be provided to the client after each removal session because the success of the procedure is dependent on client compliance by adhering to the aftercare and healing protocol according to manufacturer and product guidelines.

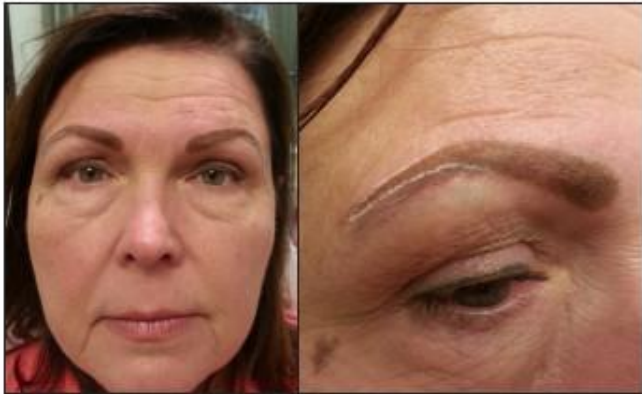In general, the recommendation for needle size for removals typically ranges from a configuration of an eight round to a fourteen round needle, and in some cases even a five round needle. The machine speed will depend on the power source, the device, the needle configuration being used, and area of the body where the removal is to be done. In most cases, age and condition of the skin will dictate speed and pressure. This is where the need for mandatory hands-on training becomes obvious! This type of work involves a certain feel to the machine or device and the skin, just like when pigmenting skin. Hands-on training will also help you gain knowledge and experience assessing the skin and monitoring it throughout the procedure to achieve the desired result and without overworking or permanently damaging the skin.

The healing time between sessions will depend on the age of the individual and the area being worked; however, the minimum is usually six weeks. The skin needs to FULLY heal between sessions. It can be helpful to inform impatient clients that allowing insufficient healing for the skin will leave the skin more susceptible to complications, such as improper healing or compromised skin integrity, and it will also result in more discomfort. Offering this information may help the client be more willing to wait the time needed before performing the next removal session.

Case study #1

This is a client who came to me with two different brow tails. One brow was darker, and the other was lighter and also had a pink-orange color. The client wanted a bit of a shape change and more even placement.

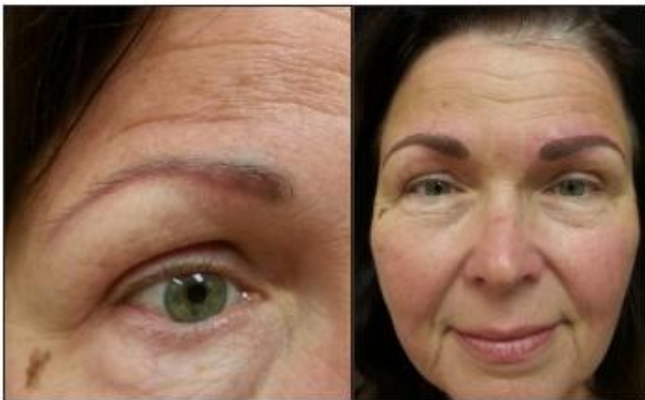My suggestion was to draw on a new design and see how much of the existing brow would be included in that design. The photos show the drawn on design with the areas outside the design marked with white



Case #1:
before removal, drawn on design (front & side view)

pencil and what I suggested for removal. Two sessions using a commercial removal product were required, and I was also able to lift the tails of her brows after the undesired pigment was removed.

For this case I used a #8 round traditional tattoo needle in a rotary machine. I made four passes in circular motions with medium to firm pressure, as this



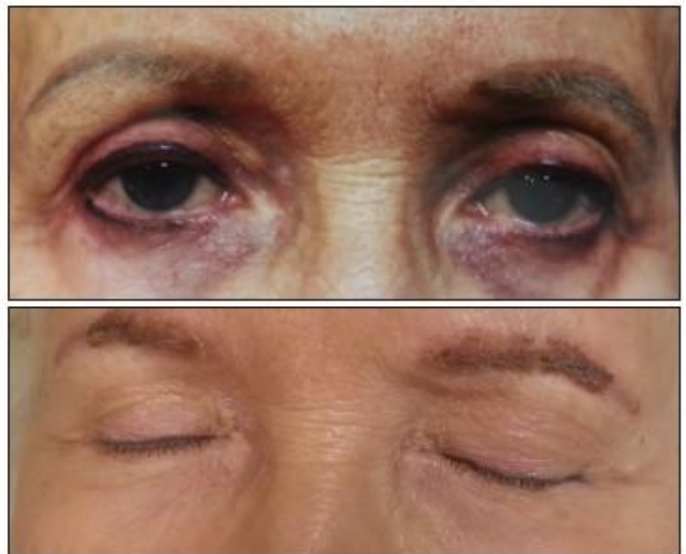Case #1:
healed after two removal sessions, followed by a new brow stroke

was thinner skin. Once the skin was properly prepared, the product was applied as directed, and then followed with cleanup and post procedure care and healing protocol.

Case Study #2

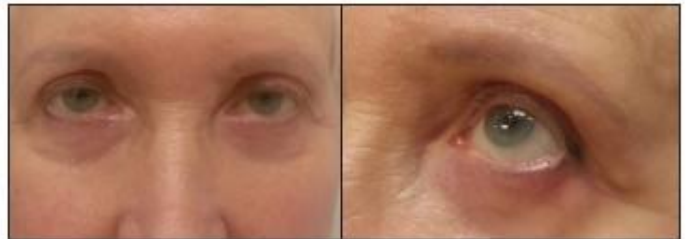This client presented with two colors of pigment (dark

gray and brown) in her brows and an uneven shape



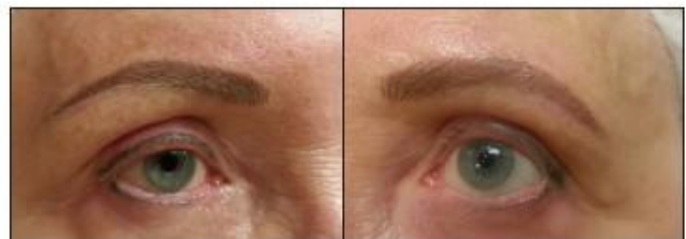Case #2:
(Top) initial presentation, two colors & uneven;
(bottom) after removal, scabs during healing process.

and depth of color. She requested better color and shape, and one that included hair strokes.



Case #2: healed after removal (front and side)

To ensure a better canvas for redesign and color, the proposal was an overall removal of her existing pigment. The removal product was used along with a #14 round tattoo needle in a rotary machine.



Case #2: healed after removal and hair stroke Correction.

In this case a #14 round needle was used because

this was an older client who has thin skin. Hand speed was conservative and pressure was medium. A total of four passes were made using a circular motion. Once the skin was properly prepared, the removal product was applied and left in place according to product directions.

Due to the age of the client, eight weeks of healing were allowed before the new pigmentation session. One removal treatment yielded an overall lighter and more even color. Because this client has such a strong muscle pull over the left brow, it sometimes looks like her brows are still uneven, but trust me, they aren't!

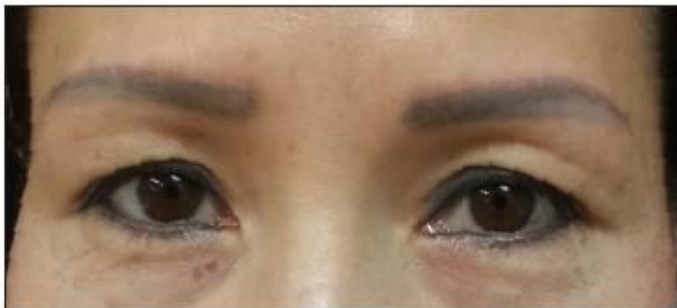The appearance just depends on what she does with her facial expression.



Case #2: hair stroke Correction after healed removal.

Case Study #3

The next case was a client who presented with a list of problems: 1) the brow shape was totally wrong; 2) a cover-up was attempted with camouflage pigment; 3) the situation was made even worse when another bad shape was put on top of the camouflage. This was a

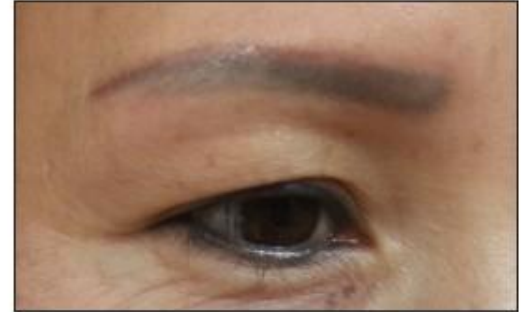


Case #3: "Healed result of first removal session"

case that called for removing as much pigment as possible, before even considering doing a new shape. Something to keep in mind is that tattoo removal products generally tend to pull pigment out, layer by

layer, and this client had approximately six layers that needed to be removed.

The treatment proposal was for total removal of about 1cm from the front of the right brow, and approximately 5mm from the front left brow. The camouflaged areas below the arch of both brows also needed to be completely removed. Titanium Dioxide can be difficult to remove, but with enough removal sessions, it will often lift out and finally reveal the darker pig-

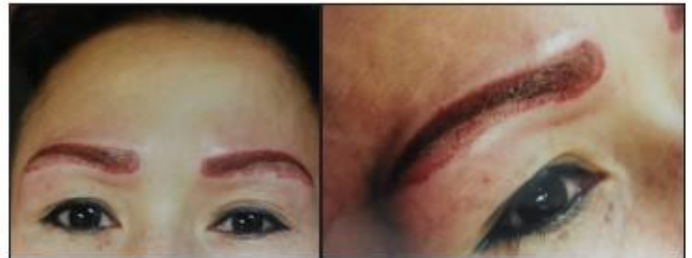

Case #3: Healed result of first removal session

ment under it.

Once the color was light enough, I was able to draw the new design to determine just what still needed to be removed. It ended up being a very small amount.

At this point there have been two complete brow removal sessions and one additional session for a small area that had more pigment to be removed. A longer healing period is being allowed before proceeding with the next removal session.



Case #3: Immediately after first removal session

These photos show the skin condition and redness that can be anticipated after a removal session. Due to the Asian ethnicity, some of the healed photos exhibit Post Inflammatory Hyperpigmentation (PIH); this will normally subside over a period of time. Allowing enough time for full recovery of the removal areas is a key factor in NOT causing excessive scar tissue.

In the first and second sessions a #14 round tattoo needle was used in a rotary machine. The pressure

was firm with tight circular motions. The removal product was applied once the skin was properly prepared and removed according to manufacturer guidelines, and then followed with cleanup and post procedure care and healing protocol.

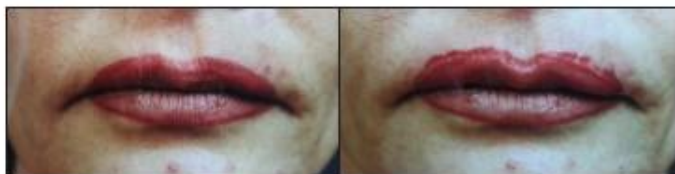

Case #3: Drawn on NEW DESIGN revealing areas under arches still needing a 3rd session

The client has not returned to have the corrective brow procedure done as drawn on to mark removal boundaries.

Case Study #4

Client #4 had an upper lip line that was WAY too high for her liking. In this case, a #8 round needle and rotary machine were used. The commercial removal product was used to remove some of the width that extended beyond the vermillion border. One removal session took away the undesired part of the original

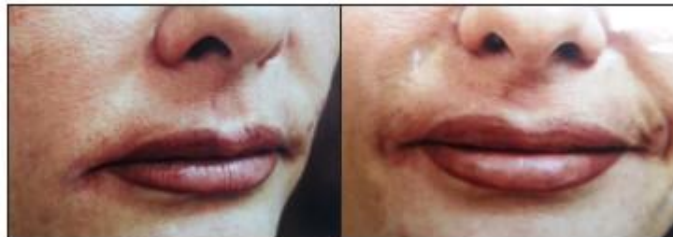

Case #4: (left) before removal of recent color refresh by another tech outside vermillion. (right) immediately after removal

design. The healed result on the upper right side was still a bit crooked, but often with removal it is hard to have it perfect, as you can't make straight movements like you do when implanting pigment. The correction procedure provided a new top edge and was based on the drawing she did. It's still slightly beyond her vermillion, but it's what she wanted and has been doing for years. Final healed photos are not yet available, but I am told by my client that the design is near perfect and just needs a bit more perfecting.

Note when working on the skin above the lip

vermillion, the tissue texture and thickness are much different than the lip tissue or the vermillion border. That is one reason for choosing a #8 round needle instead of the usual #14 round. Healing for this kind of removal is TOUGH on the client, as this is an area that stretches and is difficult to keep absolutely dry. My goal was to accomplish the removal in ONE

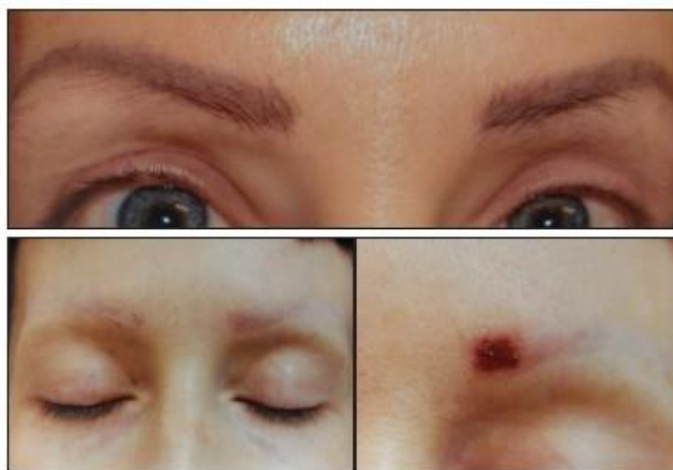

Case #4: (left) shows removal area plus color and line correction (right) crisp lip line and color blend

session. The original procedure had just recently been done, so I was fairly certain it would yield good results with a single removal session, and it did!

Case study #5

This was a client who wanted her pigmented brows COMPLETELY GONE. I performed three removal sessions, and the third was to treat a tiny bit of grey still left in the front left brow. All of the removal sessions were done with a #14 round needle. The client is out of the country right now, but reported that the



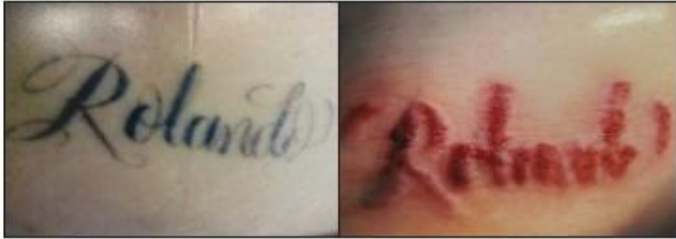Case #5: (top) before and requesting complete removal (bottom-left) healed after second removal (bottom-right) removal of small area in head of brow only.

brows are fully healed. The procedure to implant new

brows is planned when she returns in the summer.

Case study #6

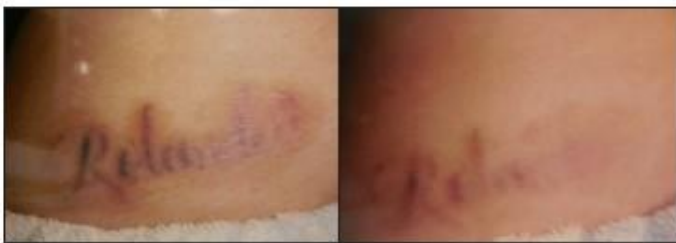Case #6 involves body art removal. Unbelievably, the before photo is AFTER seven laser removal sessions. There was also a hard rope-like bit of scar tissue built up under each letter. After the first liquid removal



Case #6:
(left) body art after 7 laser treatments.
(right) immediately after liquid removal

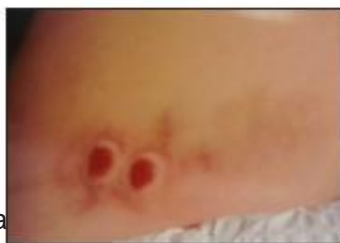session the scar tissue was broken up, and each session removed more and more until I was finally just working on tiny areas.

This client had eight sessions with me. I did not get



Case #6:
(left) healed after removal and before another.
(right) healed after more removal.

to see the final healed result because she moved out of state. However, she has since told me it is barely noticeable at all. Her ethnic heritage is Hispanic, but there was never any hyperpigmentation from the liquid removal process. She did have a slight ring of hyperpigmentation around the area from the laser when



Case #6:
body art after last removal session.

I first worked on her, which did subside later.

A #14 round needle configuration was used for all the removal sessions except the last, where I chose

to use a #8 round at a slightly lower machine speed. Because this involved the upper hip area and was subjected to clothing, the client was advised to wear a non-stick bandage during the day to prevent friction on the scab.

Conclusion

Offering tattoo removal services requires training and skill, and often involves an investment of time and patience for both the permanent cosmetic professional, as well as the client. Offering hope and help for clients with poor outcome procedure work can be very satisfying and fulfilling for any professional in the industry. However, false hope, unrealistic expectations, or lack of skill or training can easily make a bad situation even worse. I am a big believer in proper training and working on clients based on my level of expertise and within the limitations and parameters of my skill, as well as the removal products being used. Using these guidelines helps keep me and my clients safe and satisfied.

About the Author: Diane Molinaro, CPCP first trained to become a permanent cosmetics artist in 2003 after years of experience in the beauty industry, as a licensed manicurist and a professional for eyelash extensions. Diane joined SPCP in 2007, earned her CPCP in 2008, and attends at least one SPCP event every year where she is affectionately known by her nickname, Mo. Diane has a growing business in her Orange County, CA permanent cosmetic studio, and attributes that growth to continuing education and knowledge gained from SPCP, as well as other colleagues and trainers in the industry.



We don't enter the future... We create it.